



Managing Preemie Stomas: More Than Just the Pouch

Valerie E. Rogers, MS, RN, CPNP, CWOCN

This article provides a review of diseases affecting preterm neonates that may result in fecal diversion and types of stomas created during surgical intervention. Characteristics influencing ostomy management in this population, particularly skin barrier properties, are examined. Finally, ostomy equipment and pouching techniques are discussed to provide health professionals with clinically-based guidelines and practical strategies for managing premature ostomates. (J WOCN 2003;30: 100-10.)

As neonatologists, neonatal intensive care unit (NICU) personnel, and pediatric surgeons have become increasingly successful in improving survival rates of premature neonates (preemies), the surgical creation of fecal stomas to manage diseases in this population has become more commonplace. Diversion of the fecal stream allows recovery of diseased organs and surgical anastomoses distal to the enterostomy, with improved outcomes. The stoma is usually temporary and created as a stage in the surgical management of congenital or acquired disease. Caring for these low, very low, or extremely low birth weight infants with their tiny stomas and special needs can be challenging and frustrating.

Never before have more ostomy products been available for managing a wide variety of stomas and stomal complications. Many of these products are being used on premature infants with an ostomy. In general, however, caregivers lack knowledge regarding the management of preemie ostomies and are unfamiliar with ostomy equipment suitable for this population. The result is stoma care that is inappropriate for low gestational age infants, inconsistent among caregivers from shift to shift, and ineffective in containing effluent from the stoma or preventing stomal complications.

WOC nurses provide expertise in managing ostomies in a wide variety of patients. They possess specialized knowledge of skin and wound care and familiarity with ostomy products, and can be an invaluable resource for nurses, physicians, and parents involved in the care of a premature infant with a stoma. Nevertheless, care of the low gestational age infant is so specialized that WOC nurses accustomed to caring for adults will benefit from an overview of the premature ostomy patient as a unique individual with needs quite different from those of adult ostomates.

This article reviews disease conditions in the premature infant most commonly resulting in construction of

fecal diversions and the types of stomas created during these surgeries. Unique aspects of preterm infant physiology that influence pouching and stomal management, such as immature epidermal barrier function and increased percutaneous absorption, are examined. Finally, ostomy equipment and pouching techniques appropriate for the preemie are discussed in detail to provide research-based guidelines and practical strategies for caring for premature ostomates.

COMMON CONDITIONS REQUIRING STOMAS IN PREMATURE INFANTS

The great majority of fecal diversions in preemies are created for the management of necrotizing enterocolitis (NEC). Occurring in 1% to 7.5% of the newborn nursery population,¹ NEC is largely a disease of premature infants and is characterized by one or more areas of intestinal necrosis interspersed with segments of normal bowel, or skip areas. Any area of the intestine may be affected, but the terminal ileum and right colon followed by the left and sigmoid colon are the most commonly involved sites.² A triad of interrelated events in the pathogenesis of the disease has been implicated. These include availability of a substrate such as formula, ischemic mucosal injury of the intestine as occurs in perinatal asphyxia, hypothermia or vasospasm during umbilical artery catheterization, and finally, bacterial colonization.³ Infants with NEC are managed medically with bowel rest, nasogastric decompression, intravenous alimentation, transfusions, and antibiotics.

Surgical intervention is indicated only in infants who fail to respond to medical management or in whom gangrene develops or perforation of the bowel occurs. Surgery is required in 25% to 50% of newborns with NEC.⁴ Multiple areas of necrosis with skip areas of viable bowel are managed by resection of the individual necrotic segments in an attempt to preserve as

Valerie E. Rogers, MS, RN, CPNP, CWOCN, is a Pediatric Nurse Practitioner, Children's Surgical Associates, Lutherville, Md.

Reprint requests: Valerie E. Rogers, MS, RN, CPNP, CWOCN, 12140 Gray Star Way, Columbia, MD 21044; e-mail: valerierogers@erols.com.

Copyright © 2003 by the Wound, Ostomy and Continence Nurses Society.

1071-5754/2003/
\$30.00 + 0

doi: 10.1067/mjw.2003.27

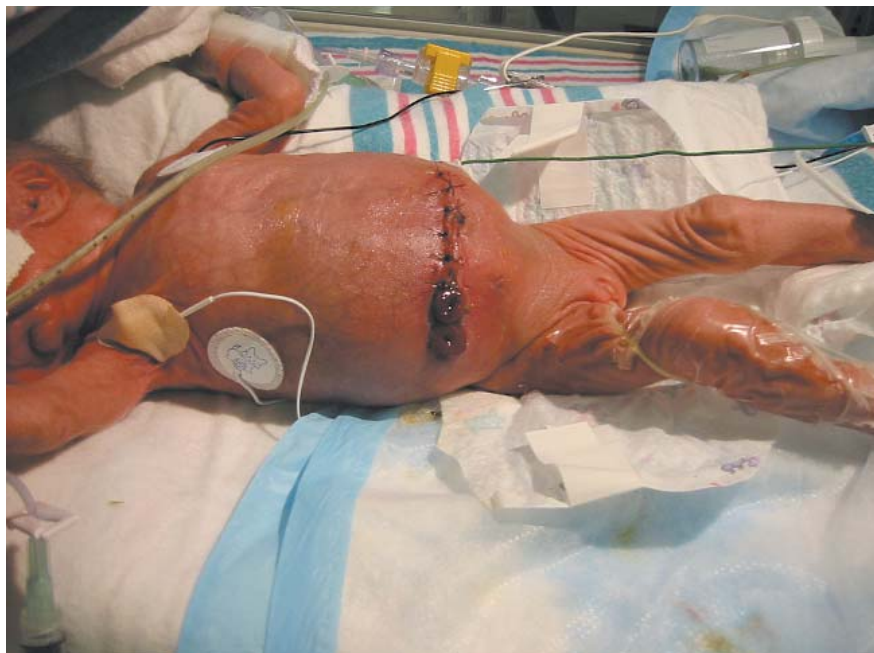

Figure 1. Double-barrel stoma within a laparotomy incision. Photograph courtesy of Beth Zimmerman, University of Chicago Children's Hospital.

much intestinal length as possible and prevent short bowel syndrome. This surgery may result in construction of multiple stomas, the proximal stoma usually being jejunum.⁴ Another approach is to exteriorize a proximal stoma only, closing the distal bowel and replacing it in the abdominal cavity,⁴ resulting in only one stoma. Traditional surgical management, however, involves creating 2 enterostomies: a proximal or functioning stoma and a mucous fistula, which allows for decompression of the distal bowel.



Stomas may be placed within the laparotomy incision⁵ to preserve as much intestinal length as possible and leave minimal scarring of the abdomen (Figure 1), or they may be brought out through separate incisions to decrease the risk of wound infection and facilitate pouching. They may be separated on the abdominal wall or brought out in close proximity,⁶ depending on the surgeon's preference and viability of the bowel. In very small preterm infants the bowel may not tolerate excessive manipulation or traction,² and stomal placement may not be totally elective. Stomas in these infants may not be matured, because sutures may compromise the survival of the mucosa, but perfusion will rapidly mature these stomas.² Closure is dependent on weight gain, feeding tolerance, and stoma output, but is never done electively less than 4 to 6 weeks after the initial surgery because of residual bowel inflammation and potential for stricture formation up to several weeks following resolution of NEC.⁴

Conditions other than NEC requiring fecal diversion in infants generally allow full-term gesta-

tion and do not have an increased incidence in preterm neonates, although occasionally they may be seen in the premature population. The most common of these include anorectal malformations, Hirschsprung disease (HD), meconium ileus, and intestinal atresias. Anorectal malformations, occurring in 1 in 4000 births,⁷ encompass a wide range of congenital anomalies involving the gastrointestinal, urinary, and reproductive systems and result in an abnormal communication between the rectum, genitourinary tract, or perineum.⁸ Anorectal malformations may require immediate surgery if the passage of urine or stool is obstructed. Feces is diverted via descending colostomy, either double barrel⁹ or loop,¹⁰ until the infant is old enough to tolerate definitive surgical correction of the defect. Complex, rare anorectal malformations, such as bladder or cloacal exstrophy, require more extensive surgical management and may involve multiple urinary and fecal stomas on a temporary or permanent basis.

One in 5000 newborns presents with HD. HD is characterized by the absence of ganglion cells in the distal bowel, causing a lack of peristaltic waves and spastic contraction of the affected segment with resultant difficulty in passing stool. Up to 90% of all cases are diagnosed during the neonatal period after the infant fails to pass meconium during the first 24 hours of life,¹¹ followed by the development of abdominal distension and vomiting. Some infants now undergo one-stage or primary endorectal pull-through operations, in which the affected segment of colon is removed without creating a fecal diversion. Commonly, however, a de-

—◆—
*Stomas may
be placed
within the
laparotomy
incision to
preserve as
much intestinal
length as
possible and
leave minimal
scarring.*
—◆—


*Complicated
meconium
ileus occurs
when
meconium
contaminates
the
peritoneum in
utero or in the
immediate
perinatal
period.*


scending or transverse, loop or end colostomy^{11,12} is created above the aganglionic segment to keep the bowel decompressed until definitive surgery is performed outside the newborn period. Three to 12% of infants with HD have total colonic aganglionosis.¹³ In these infants, ganglion cells are absent throughout the entire colon and possibly the distal small bowel, necessitating construction of a diverting ileostomy.

Meconium ileus results from abnormalities of exocrine mucous secretion, which contribute to the production of a thick, sticky meconium that obstructs the small intestinal lumen. Ninety-five percent of patients with meconium ileus will have cystic fibrosis.¹⁴ Obstruction usually occurs in the distal 15 to 30 cm of terminal ileum. Historically, treatment involved resection of the dilated ileum and formation of an ileostomy. These procedures had the disadvantage of resecting bowel in an infant with a disorder that would affect intestinal function,¹⁵ thus compounding malabsorption. Current management of simple meconium ileus involves instillation of N-acetylcysteine into the bowel lumen through one or more enterotomies to soften inspissated stool, followed by manipulation of the bowel to move the meconium into the colon¹⁶ where it can easily be expelled.

Complicated meconium ileus occurs when meconium contaminates the peritoneum in utero or in the immediate perinatal period. Bowel perforation, with spillage of meconium, results most commonly from meconium ileus, volvulus, or intestinal atresia or stenosis. Surgical resection of involved bowel is usually required. If the integrity of the bowel is such that anastomosis cannot be performed safely, a proximal ileostomy is exteriorized.¹⁵

Meconium ileus unrelated to cystic fibrosis has been reported in very low birth weight newborns. These premature babies produce few stools and abdominal distention develops, occasionally leading to bowel necrosis or perforation.¹⁶ Risk factors include intrauterine growth retardation, maternal eclampsia, hyaline membrane disease, intraventricular hemorrhage, and patent ductus arteriosus. Treatment of choice is fluoroscopically controlled water-soluble hyperosmolar contrast enemas.¹⁶ Operative management, including enterostomy, is avoided, if possible, because of the high risk of iatrogenic bowel injury in this fragile population.

Intestinal atresia, although a common cause of bowel obstruction in the neonate, is relatively rare, occurring in about 1 in 5000 live births.¹⁷ Atresia, or complete disruption of the lumen of the bowel, most often occurs in the small intestine. Duodenal atresia is thought to be the result of failure of recanalization of the bowel lumen during the eighth to tenth week of gestation and is associated with Down's syndrome. Jejunoileal atresias probably occur as the result of intrauterine ischemic injury.¹⁸

Up to 20% of infants with one small bowel atresia are found to have additional atresias.¹⁷ Surgery is performed emergently and involves resection of involved bowel with end-to-end anastomosis. Stomas are created only in unstable patients with peritonitis, vascular compromise, or meconium ileus. In these cases, both proximal and distal stomas are exteriorized and the stomas may not be matured because of an increased incidence of systemic sepsis and mortality.¹⁸

PRETERM INFANT SKIN CHARACTERISTICS INFLUENCING POUCHING

Preterm infants are physiologically and structurally immature, requiring specialized care. This is particularly true for the premature neonate with an enterostomy. A clear understanding of the unique differences between the preemie and the adult or term newborn who may require an ostomy is necessary to develop an appropriate plan of care for the preterm ostomy patient. The most important difference to consider in the preemie's stomal management is the development of the epidermal barrier function of the skin.

The development of the epidermal barrier affects the premature infant's ability to adapt to the environment. Skin acts as an interface between the infant's internal environment and the outside world. It regulates transepidermal water loss and helps maintain electrolyte homeostasis. It functions in thermoregulation and minimizes caloric expenditure. The skin provides protection from environmental toxins, trauma, microorganisms, and ultraviolet radiation. Not least, tactile sensation is perceived through the skin. To perform these functions adequately and thereby decrease morbidity and mortality, a competent epidermal barrier is essential.

The epidermal barrier resides in the stratum corneum or the outermost layer of skin. It forms in utero during the third trimester and increases in maturity with increasing gestational age. Full-term infants are born with a competent barrier similar to that found in adults.¹⁹ Premature infants, however, have a far less well-developed barrier, leaving them ill equipped to cope with the outside environment. The stratum corneum in adults and term infants has 10 to 20 layers, compared with only 2 to 3 layers in a preterm infant of less than 30 weeks' gestation or virtually no stratum corneum in a 24-week preemie.²⁰ This results in increased transepidermal water losses (TEWL), as well as increased transepidermal absorption of topical agents and increased susceptibility to chemical and mechanical injury.

The dermal-epidermal junction, normally characterized by undulations or rete ridges, which help bond the 2 layers of skin, is more flat in the premature neonate, with fewer anchoring elements to

bond the epidermis to the dermis. Epidermal stripping readily occurs with the removal of adhesives applied to premature skin, because they create a stronger bond with the epidermis than the epidermis has with the underlying dermis. The skin is also more susceptible to friction injury and blistering. These breaches in the epidermal barrier leave the preemie vulnerable to invasion of microorganisms as well as increased TEWL and percutaneous absorption.

By 32 weeks' gestation, barrier function of the skin has been found to be compatible with that of adults.¹⁹ In infants of less than 32 weeks' gestation, rapid maturation of the epidermis occurs after birth, resulting in skin barrier properties resembling that of a term infant by 2 weeks of age.²¹ In very low birth weight infants, however, skin maturation is delayed. Kalia et al¹⁹ found that in the ultra low birth weight infants of 23 to 25 weeks' gestation, maturation can take as long as 8 weeks.

Numerous environmental factors can postpone barrier maturation. Epidermal development is greatly delayed in a high humidity environment, such as a humidified isolette.¹⁹ Application of occlusive adhesive and pectin barriers, a common practice in neonatal intensive care nurseries, similarly delays epidermal maturation,²² as does administration of postnatal parenteral steroids.¹⁹ Application of semioclusive transparent dressing to the premature epidermis, a strategy used in some NICUs to decrease TEWL and epidermal shearing, has not been found to impede epidermal development,²² however, possibly because these dressings allow transepidermal fluid exchange.

Several other developmental factors must be taken into consideration in the management of the premature infant's enterostomy. In the newborn, the ratio of surface area to body weight is 3 times that of an adult.²³ The surface area to body weight ratio is even greater in the preemie. Combined with an immature barrier, this results in greater transepidermal absorption of topically applied substances in the preemie population. The antibacterial acid mantle of the epidermis, which develops within 4 days of birth in the term infant and provides protection against certain microorganisms, forms more slowly in the preemie²⁴ and is easily disrupted by the application of topical agents. Finally, skin integrity is directly related to nutritional status. Preterm infants are at risk for deficiencies in nutrients stored during the latter part of pregnancy. Neonates with stomas, furthermore, are at risk of malabsorption²³ resulting from a shortened gastrointestinal tract and decreased absorptive surface area.

Clearly, pouching the preterm infant's stoma safely and effectively requires deliberation beyond that of choosing the brand of ostomy appliance. Careful thought must be given to the unique characteristics of the premature neonate. These include

delayed epidermal barrier development, increased transepidermal absorption, greater surface-area-to-body-weight ratio, an unstable acid mantle, an incompetent dermal-epidermal junction, and nutritional deficiencies.


PREEMIE STOMA MANAGEMENT

Stomal management of the premature infant should incorporate principles applicable to the care of any patient with an ostomy. The skin must be protected from effluent, which can be damaging because of its enzyme content, pH level, and liquid content. The stoma must be protected from damage resulting from improper pouching technique. The peristomal skin must be protected from mechanical trauma resulting from the use of aggressive adhesives, improper adhesive removal, or inappropriate cleansing. Finally, the skin, or in the case of the preemie, the entire person must be protected from damage caused by incorrect or inappropriate use of ostomy products. Many ostomy products and management techniques used effectively on an older child or adult ostomate may not be safely used with the preterm infant. Care of the preemie with an enterostomy and appropriateness of various commercial ostomy products will be discussed.

When an ostomy appliance needs to be replaced, care must be taken to avoid damaging the peristomal skin during pouch removal. A soft cloth dampened with warm water should be used to loosen the barrier adhesive. Soap, which contains surfactants, may be helpful to decrease the amount of friction required to remove a particularly adherent barrier from the skin without trauma.²⁵ The soiled pouch should be removed by gently pushing down on the skin to separate it from the wafer while lifting up on the pouch.

Adhesive removers, often used to minimize traumatic pouch removal in adults, should not be used on infants. There are several reports of skin reactions consistent with toxic epidermal necrolysis occurring in adults and children after exposure to petroleum distillates, an ingredient contained in adhesive removers. Ittmann and Bozynski²⁶ reported the development of toxic epidermal necrolysis in an infant of 26 weeks' gestation after a commonly used adhesive remover was used to remove electrodes following an electroencephalogram.

Furthermore, adhesive removers contain alcohol, which is well documented as causing topical and systemic effects in infants, including skin blistering, burns, necrosis, and death from elevated blood alcohol levels.^{27,28} Use of adhesive remover should be limited to situations in which adhesives are so bonded to the infant's skin that they cannot be removed without risking damage to the fragile epidermis. After application, the skin should be thoroughly washed and rinsed to remove any chemical residue. Pectin remaining on the skin after pouch removal should not interfere with



By 32 weeks' gestation, barrier function of the skin has been found to be compatible with that of adults.




Table 1. Fecal ostomy appliances for preemies

Manufacturer/ distributor	Appliance name/ catalog No.	Infant size*	Characteristics
Dansac A/S, Fredensborg, Denmark; US importer/distributor: Incutec, Inc Hollister, Libertyville, Ill	CombiMicro Mini Infant Soft D Pouch No. 31010-1320 (clear)	1 to 2.5 kg	Barrier round, 6.3 cm; barrier attached to pouch; color clear; extras: microporous, breathable 1.5-cm adhesive picture-framing; starter hole 8 mm; stoma size 9 to 25 cm
	Pouchkins Premie Ostomy Pouch No. 3777	<1 kg	Barrier round, 5 cm; barrier separate from pouch; color clear; starter hole: none; pouch closed end, capacity 10 mL; stoma size up to 16 mm
	Pouchkins Newborn Ostomy Pouch No. 3778	1 to 2 kg	Barrier round, 6.3 cm; barrier separate from pouch; color clear; pouch capacity 100 mL, w/drain tube (must cut off for thicker stool); pouch opening at barrier, 2.5 cm × 3.8 cm oval; starter hole: none; stoma size up to 22 mm
	Pouchkins One-piece Pediatric Pouch No. 9768	1.5 to 3 kg	Barrier square, 7 × 7 cm; barrier attached to pouch; color clear; pouch length 16 cm; starter hole: none; stoma size up to 38 mm
Incutec, Inc., Kernersville, NC	Premie Pouch, multiple options: Nos. 70S1020 through 70S1328	<1 to 2 kg	Barrier round or daisy shape, 5 graduated sizes 3.8 to 8.9 cm; barrier options: separate or attached to pouch, regular or double thickness; color clear; pouch 6 × 27 cm cut to length; starter hole options: none or 6 mm; stoma size up to 25 mm depending on barrier size
Marlen, Bedford, Ohio	Infant Ileostomy Pouch No. 563306	1 to 2 kg	Barrier round, 3.3 cm; barrier attached to pouch; color clear; extras: microporous, breathable adhesive 1.8 cm picture-framing; pouch capacity 150 mL; starter hole 5 mm; stoma size 5 to 25 mm
	Pediatric Ileostomy Pouch No. 564306	>2 kg	Barrier round, 5.0 cm; barrier attached to pouch; color clear; extras: microporous, breathable adhesive 1.8 cm picture-framing; pouch capacity 200 mL; starter hole 5 mm; stoma size 5 to 32 mm
Nu Hope Laboratories, Pacoima, Calif	Neonatal Pouch Systems Nos. 7000, 7001, 7002	<1 to 2 kg	Barrier round, 4.4 cm; barrier separate from pouch; color: flesh-tone skin-side w/clear top; extras: support shield 2 styles, flat w/21 mm opening or 3 mm convexity w/12 mm opening; use w/adjustable support belt; pouch 6 × 22 cm + 2 larger sizes; starter hole: none; stoma size up to 20 mm; custom orders for difficult stomas
T.G. Eakin Limited, Comber, County Down, Northern Ireland; importer/distributor: ConvaTec	Eakin Fistula & Wound Pouch No. 839210	1 to 2.5 kg	Barrier oval, 6.5 × 5.3 cm; barrier attached to pouch; color clear; extras: fold-and-tuck closure; barrier of Eakin Cohesive; starter hole 4 mm, stretch rather than cut to fit; stoma size 4 to 20 mm

*Estimate based on experience when manufacturer recommendation not available.

pouch adherence and is not damaging to the skin, so it need not be vigorously removed.

Peristomal skin should be gently cleansed with water between pouch applications. The use of soap is discouraged because any residue left under the barrier could cause a chemical dermatitis. If soap is used, it should be a pH neutral soap without antibacterial or deodorant additives and it should be thoroughly rinsed from the skin before pouch reapplication. Alkaline soap has been shown to disrupt the acid mantle of the preterm infant's skin for up to 7 days,²⁹ thereby crippling an important barrier to infection. Soaps containing moisturizers should be avoided because they will interfere with pouch adherence. Commercial infant wipes are

lanolin based and most contain alcohol, and thus they are not suitable for cleansing peristomal skin.

Skin barrier wipes or skin sealants are plasticizing agents applied to the skin to create a barrier. They can protect skin from the corrosive effect of stool and are used effectively in the incontinent population. Skin sealants are sometimes used by adult ostomates to protect peristomal skin from epidermal stripping, which may occur during pouch removal. However, because they contain alcohol as a solvent, including most "no sting" versions, skin sealants should not be used on the preterm infant.

Currently, the only alcohol-free skin sealant on the market is Cavilon No Sting Barrier Film (3M,



Figure 2. Examples of appliances for pouching fecal stomas in the preemie.

Table 2. Ostomy accessories appropriate for preemies

Product category	Brand name/catalog no./manufacturer
Caulking strips	Ostomy Strip Paste No. 2655, Coloplast, Marietta, Ga Skin Barrier Caulking Strips No. 4068, Nu-Hope Laboratories, Inc
Charcoal filters	FiltrOdor Pouch Filters No. 0509, Coloplast
Gel crystals	Ilesorb Absorbent Gel Packets No. 87210, Cymed Ostomy Co, Berkeley, Calif Nu-Sorb Absorption Grains No. 1460, Nu-Hope Laboratories, Inc
Moldable barriers	Eakin Cohesive Seals 2" No. 839002, ConvaTec, Princeton, NJ Barrier No. 54 (2" Moldable Barrier Disks) No. 4304, Nu-Hope Laboratories, Inc

St Paul, Minn). This product consists of hexamethyldisiloxane, acrylate copolymer, and polyphenylmethylsiloxane. Irving³⁰ studied the use of Cavilon as a protective barrier beneath transparent semipermeable adhesive dressings used to secure intravenous cannulations on infants in a NICU. The study showed a significant decrease in epidermal stripping without adverse effect on skin integrity after removal of the dressing and barrier film, even in the subset of infants less than 32 weeks' gestation and less than 21 days of age. Although this study provides some evidence that Cavilon may be used safely in premature infants, further study is needed to confirm the safety of alcohol-free barrier wipes for use in the preterm population before routine use can be recommended.

A secondary consideration in the use of skin sealants beneath ostomy appliances is that the plasticized film may actually reduce adherence of the appliance³¹ by preventing contact with the skin. If a barrier wipe must be used on the preterm

neonate, only an alcohol-free sealant should be used and it should be allowed to dry thoroughly to allow any chemical component to evaporate before pouch application.

Several issues need to be considered when choosing an appliance for a preterm infant. These considerations include the size of the infant's abdomen, diameter and profile of the stoma, number and proximity of stomas, consistency and digestive enzyme content of the effluent, volume of stool and gas effluent from the stoma, presence of abdominal contours and scars, and peristomal skin integrity, as well as cost and product availability.

A pouch and pectin-based barrier that fit the infant's abdomen must be selected. A number of manufacturers of ostomy products carry pouches sized to fit infants, including low birth weight and very low birth weight infants. Table 1 lists several ostomy pouches appropriate for preemies and infants, and Figure 2 shows some of those appliances. Table 2 presents some of the available

◆

Adhesive removers, often used to minimize traumatic pouch removal in adults, should not be used on infants.

◆

pouching accessories useful in the neonatal population. Familiarity with available products is imperative in determining which product is most appropriate for a particular patient or situation. Pouches used on preemies should be clear to allow inspection of the stoma and effluent. Low birth weight infants with a single stoma to pouch will require a smaller pouch and barrier that will not cover their entire abdomen. Larger infants, or infants with more than one stoma to pouch within the same appliance, will need a pouch with a larger barrier.

Barriers come in many sizes and shapes, including round, square, and daisy-shaped. Landmarks on the infant's abdomen may dictate which shape will work best. A daisy-shaped wafer, for example, may fit more easily around an umbilicus or adjacent mucous fistula. Most barriers, however, can be custom trimmed to fit around abdominal landmarks. Some pouches come with separate barriers, and these barriers may be easier to trim. Pouches with attached barriers, on the other hand, will allow for fewer steps in the pouching process. Barriers without starter holes allow for more lateral placement of the stoma opening when pouches need to be shifted away from an incision line or another stoma, but the opening is more difficult to cut without a starter hole. When using a barrier with a precut starter hole, care must be taken to ensure that the opening is not larger than the stoma.

The type of appliance and barrier will be influenced by the placement of the stoma in the bowel. An appliance with no hydrocolloid skin barrier, or with a very thin barrier, although allowing for conformability to abdominal contours, may not withstand caustic effluent from a proximal ileostomy or jejunostomy, and a pouch with a thicker skin barrier may be required. The addition of a supplemental barrier under the pouch barrier may improve wear time. Several pectin-based moldable barriers and caulking strips are available that are able to withstand exposure to corrosive effluent. They can be shaped and trimmed to fit around any stoma for added protection against tunneling of effluent under the pouch. Karaya is never used as a barrier on a premature infant because it releases acetic acid when it comes in contact with moisture and may burn the skin.³¹

Use of adhesive on preemie skin is discouraged to prevent epidermal stripping with removal. Most preemie pouches do not have a tape adhesive surrounding the pectin barrier. Generally, the pectin will bond with the skin and maintain an adequate pouch seal. However, a pouch incorporating a gentle adhesive picture framed around the wafer may prolong pouch life if the edges of the skin barrier loosen with continued exposure to extrinsic moisture.

Flexibility is an important consideration when choosing a preemie pouch. Two-piece pouching

systems, which incorporate firm, snap-together rings or flanges, should not be used on premature infants. They require pressure to snap the 2 pieces together, which would not be well tolerated by the preemie. Even if used as a one-piece system by attaching the 2 pieces of the pouching system prior to application, visibility of the stoma and peristomal skin is decreased and the plastic flange does not allow adequate flexibility. Pouching systems in which the hydrocolloid barrier is available separate from the pouch but does not include a plastic flange are acceptable. When choosing an appropriate appliance, however, it is important to consider that NICU nurses may be unfamiliar with ostomy care, and it is important to design the simplest pouching system with the lowest likelihood of complications.³² A common mistake in using the two-piece pouch, for example, is for caregivers to apply the pouch directly to the skin, omitting the barrier and leaving the peristomal skin exposed.

A stoma will decrease in size over 6 to 8 weeks postoperatively and should be remeasured with each appliance change until the size is stabilized. The barrier should fit closely around the stoma.^{31,33} Cut the stomal opening no more than $\frac{1}{8}$ inch larger than the stoma, allowing no more than $\frac{1}{16}$ inch of peristomal skin to be exposed to effluent. Hydrocolloid skin barriers are flexible and will melt and mold around the stoma without causing damage provided the opening is not smaller than the stoma. A finger should be run around the cut edge of the barrier to smooth the rough edges before pouch application.

Uneven skin surfaces caused by incisions, skin creases, and other obstacles should be leveled before pouch application. Supplemental patches of moldable barrier or caulking strips can be used to fill in gaps. A peristomal surface that is flat, with a 1-inch border extending away from the stoma,³⁴ will provide the most effective pouching surface.

Skin barrier pastes are used to protect peristomal skin from effluent and to create a level pouching surface. Although commonly used on infants, they should be avoided because of their alcohol content. They may also contain formaldehyde, although in quantities small enough to avoid being listed in the ingredients. A noncommercial, alcohol-free paste can be created by mixing skin barrier powder and glycerin.³¹ The ingredients are mixed in proportions to achieve the consistency of toothpaste and then applied with a syringe. Without alcohol as a preservative, however, this mixture will quickly harden. Small amounts should be mixed for one-time use only.

When other options fail and commercial paste is required to keep a pouch in place, a low-alcohol paste should be used. Paste should be applied to the barrier with a syringe to minimize the amount used, and it should be applied only in areas where adhesion is most problematic. The paste should be




*Flexibility is an
important
consideration
when
choosing a
preemie
pouch.*


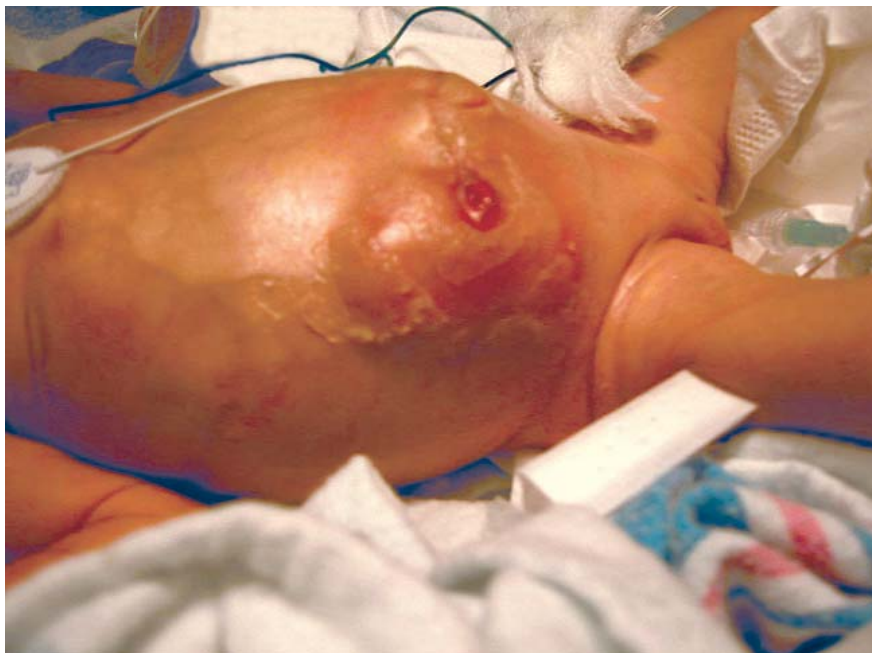

Figure 3. Premature infant with flush stoma. Photograph courtesy of Beth Zimmerman, University of Chicago Children's Hospital.

allowed to “air out” at least 1 minute to maximize evaporation of the alcohol before pouch application. Any skin barrier paste, however, including noncommercial paste, should be used with caution. The bond created between the skin and the pouch may be greater than the bond between the skin layers and may strip the epidermis when removed. Paste should be used only when other options to increase pouch wear time have been exhausted and when wear time with paste usage is expected to be at least 48 hours. This will allow the paste to degrade, thereby easing removal. Commercial adhesive enhancers, such as benzoin and cements, must never be used on a preemie.

A flush (Figure 3) or retracted stoma presents challenges in maintaining a pouch seal. The addition of a moldable barrier or caulking strip beneath the pouch barrier adds gentle convexity and may improve wear time. One manufacturer carries a convex insert or “support shield” for use with infant/preemie pouches. This may provide occasional benefit for the infant with a very soft abdomen to help the stoma protrude above skin level. Care, however, must be taken to cut the stoma opening in the semirigid insert large enough to prevent laceration of the stoma.

An infant's pouch needs to be able to accommodate a greater amount of gas than that of an adult because of air swallowing that occurs during sucking³⁵ and crying. Pouches filled with air can quickly compromise the pouch seal. Some infant pouches come with a built-in charcoal filter, which allows the release of gas without a detectable odor. Although no preemie pouches are available with a

built-in filter, a stick-on charcoal filter can be added to an existing pouch. The filter is placed high on the pouch where it is least likely to be in contact with liquid effluent, and a hole is pierced through both the center of the filter and the pouch to allow gas to escape. Air-filled pouches, as with pouches containing stool, should be emptied frequently to prevent pressure from compromising the seal.

Peristomal skin can be damaged by epidermal stripping from traumatic pouch removal, tunneling of caustic effluent under the barrier, sensitivity to ostomy products, or infections such as moniliasis. Loss of the epidermis results in “weeping” of serous exudate. This fluid accumulation under the pouch can decrease adhesion. Treatment of the underlying cause and reevaluation of the pouching system is essential. Fungal infections, which can proliferate in the warm, moist environment beneath the barrier and erode the skin, can be treated with nystatin powder applied to the involved area, with excess being gently brushed away before pouching. Alternatively, the powder can be mixed with water, painted over the involved area, and allowed to dry before reapplying the pouch.³⁶

To ensure dryness of the peristomal skin before pouch application, a skin barrier powder can be applied to weepy areas prior to pouching to absorb moisture and protect the peristomal skin. Skin barrier powders are alcohol free and safe to use on preterm infant skin. However, the contribution of inhaled powder to severe respiratory symptoms and death in infants has been well documented.^{37,38} When applying skin barrier powder

An infant's pouch needs to be able to accommodate a greater amount of gas than that of an adult because of air swallowing that occurs during sucking.

Table 3. Barrier products appropriate for denuded preemie skin

Barrier ointment/ paste	Manufacturer
Calmoseptine Ointment NCD No. 0799-0001-03 (2.5 oz tube)	Calmoseptine Inc. Huntington Beach, Calif
Critic-Aid Anorectal Skin Paste No. 1944/1944 (2.5 oz tube)	Coloplast Marietta, Ga
Ilex Skin Protectant Paste No. 4271-81 (2 oz tube)	Medcon Bio Lab Technologies, Inc Grafton, Mass
Sensi-Care Protective Barrier No. 325614 (4 oz tube)	ConvaTec Princeton, NJ

Pouch wear time for the preterm infant will not be comparable with that for an older child or adult.

to the infant, care must be taken to prevent aspiration of aerosolized powder. Only the minimum amount of skin should be used, and excess powder should be gently wiped away rather than blown away. The infant's face should be shielded while applying the powder. The bottle opening can be enlarged, allowing powder to easily be sprinkled without squeezing the bottle and creating a "puff" of powder. Alternatively, powder can be applied to a secondary surface, such as a gloved finger or gauze, and dabbed onto the skin. If the use of antifungal or skin barrier powders limit pouch adhesion, they can be "sealed" by patting the powder with a damp finger and allowing the area to dry.³¹ Any areas continuing to weep should be retreated with barrier powder in like manner until the exudate is contained.

Pouch adhesion may be limited by liquid effluent pooling around the stoma and degrading the barrier. This situation is especially problematic with ileostomies and jejunostomies. Measures should be taken to wick the liquid stool away from the stoma. Pouches can be angled to the side rather than toward the feet, allowing the liquid to drain away from the stoma while the infant is in a supine position. A pouch with a drainage spout can be connected to continuous drainage if the effluent is high volume and liquid. Gel crystals that absorb liquid several times their weight, similar to the product in disposable diapers, are commercially available and can be used in preemie pouches. An easy, inexpensive, noncommercial method of wicking away liquid effluent is to place cotton balls within the pouch. If intake and output is being monitored, the cotton balls or gel crystals can be weighed in and out for accurate measurement of output.

After leveling the pouching surface, ensuring that the peristomal skin is completely dry, and applying the pouch, the barrier should be warmed.

This can be accomplished by placing a hand over the barrier for 1 or 2 minutes after pouch application. The importance of this step should not be minimized. Warming the barrier allows it to mold to the contours of the infant's abdomen and increases adhesion of the barrier to the skin, improving wear time. Heating the barrier under a radiant warmer is discouraged because the amount of heat absorbed into the wafer is not controllable and an overheated barrier can easily burn fragile skin.

Pouch wear time for the preterm infant will not be comparable with that for an older child or adult. Factors such as liquid effluent, oily effluent from an infant receiving enteral supplementation with medium chain triglyceride oil, a humidified environment, and a small pouching surface all decrease barrier adhesion. An initial goal for pouch adherence may be 24 hours. However, acceptable wear time may be 12 to 48 hours depending on the condition of the infant and the stoma, the volume of output, and other obstacles to pouch adhesion. If the infant is not being fed, output will be minimal and the pouch may be left on for several days. When stomal output is continuous, though, care should be taken when leaving a pouch on for more than 2 to 3 days. Erosion of the barrier may allow undetected undermining of effluent resulting in injury to the peristomal skin.

It is always preferable to pouch a stoma to protect the peristomal skin from injury, particularly with an ileostomy or jejunostomy. Sometimes, though, despite the best pouching system, pouches will not adhere to the preemie's abdomen. If the skin is becoming denuded from caustic effluent or repeated efforts at repouching, a nonpouching option for managing the stoma may be used for a short time. The peristomal skin must be protected from effluent by an occlusive barrier ointment such as petrolatum or zinc oxide. If the skin is denuded and oozing, however, these products will not adhere. A skin barrier powder can be applied to denuded areas, followed by liberal application of a protective ointment. Alternatively, the powder and ointment can be mixed together and applied to the excoriated skin.³⁶

Commercial barrier ointments are available that will adhere to severely denuded skin and may be helpful to protect the skin from caustic effluent. Table 3 lists some products useful for this purpose. The ointment does not need to be removed from the skin, and routine removal may traumatize the skin. Covering the ointment with a layer of petrolatum or petroleum-impregnated gauze will allow easy cleaning of effluent from the skin without removing the protective barrier ointment. Finally, fluffed gauze or a diaper can be placed around the stoma to absorb effluent.

In severe cases of peristomal denudation, some neonatal centers will consider discontinuing enteral feedings briefly to limit stool production and allow the skin to heal. As soon as the infant's skin

KEY POINTS

- Although guided by principles that are the same for all patients with an enterostomy, managing the ostomy of a premature infant is not comparable with managing the ostomy of an adult, child or even a full-term infant and must take into consideration the unique characteristics of the preemie.
- Research-based evidence must guide the use of every substance used in caring for the premature infant with a stoma. Products and practices used safely in the adult population may pose a risk to the preemie.
- The simpler the pouching system that will maintain a good seal for 24 to 48 hours, the more reproducible it will be for the multiple caregivers involved in the care of the premature infant with an ostomy.

condition improves enough to maintain a pouch seal, pouching should be reinstated. Likewise, if the volume of effluent increases, or the skin condition worsens, attempts should once again be made to pouch the infant's stoma.

Every effort should be made to develop a pouching system for the preemie that uses as few products as possible. The easier the system, the more likely it is to be followed by multiple caregivers. The use of fewer products will also decrease cost. Most importantly, decreasing skin exposure to products that have the potential for transcutaneous absorption will safeguard the health of the preterm infant with an ostomy.

SUMMARY

Care of the preemie with an enterostomy can be challenging. Tiny stomas no larger than a pencil eraser, multiple stomas, flush or prolapsing stomas, and stomas in or adjacent to wounds contribute to the challenge.²³ To provide appropriate and effective ostomy care, a thorough understanding of the preterm neonate is essential. Knowledge of underlying disease conditions resulting in fecal diversion and the types of stomas created give clues to difficulties encountered in maintaining an effective pouching system. An understanding of characteristics of the premature infant will guide ostomy care and the safe use of ostomy products. Finally, familiarity with appropriate ostomy products will allow development of a stomal management plan appropriate for the unique needs of every preemie.

FUTURE DIRECTIONS

Disagreement exists among WOC nurses in practice as well as in the literature regarding the appropriate use of ostomy products on the preterm infant. Research-based ostomy management guidelines must be developed. To determine the extent of the problem, descriptive studies defining product use and pouching practices in NICUs could be carried out. Once current practice is outlined, best practice based on available re-


search can be developed into a practice guideline, similar to the tool developed by the Association of Women's Health, Obstetric and Neonatal Nurses and the National Association of Neonatal Nurses in their evidence-based clinical practice guideline *Neonatal Skin Care*.³⁹

Research to establish the safety of currently available products for use with premature infants would expand options for stoma management when simple pouching fails to give adequate protection. An example of this is further evaluation of the use of alcohol-free barrier wipes on preemies. Appraisal of nonpouching options in the management of difficult stomas that have failed pouching could be another area of investigation. For instance, dressings that are effective at wicking effluent away from the stoma and protecting peristomal skin, while being cost effective and allowing measurement of output, could be evaluated. Use of calcium alginate as a peristomal dressing, for example, presents a theoretic risk of calcium absorption through the intestinal mucosa, but this risk has never been assessed in preterm infants.


Further research into the development of new ostomy products also needs to be encouraged. For example, skin barriers that allow continued maturation of the underlying epidermis in the extremely low birth weight infant would be valuable, because these infants experience increased morbidity and mortality as a result of epidermal barrier failure. Development of skin barrier pastes safe to use on preemies would improve management options. In conclusion, determining best practice for preemie ostomy care and the development of safe products for use on this population are in their infancy and remain wide open and essential fields of research.

Acknowledgment

I would like to recognize members of the WOCN Society and the American Pediatric Surgical Nurses Association for generously sharing their photographs and experiences with preemie pouching. Without their encouragement and input, this article could not have been written.



An
understanding
of
characteristics
of the
premature
infant will
guide ostomy
care and the
safe use of
ostomy
products.



REFERENCES

1. Garvin G. Caring for children with ostomies. *Nurs Clin North Am* 1994;29:645-54.
2. Pokorny WJ. Necrotizing enterocolitis. In: Spitz L, Coran AG, editors. *Rob & Smith's operative surgery: pediatric surgery*, 5th ed. London: Chapman & Hall Medical; 1995. p. 411-23.
3. Roberts P. NEC: etiology, treatment, prevention, and nursing care. *Crit Care Nurse* 1990;10:38-55.
4. Caty M, Azizkhan R. Necrotizing enterocolitis. In: Ashcraft W, editor. *Pediatric surgery*, 3rd ed. Philadelphia: W. B. Saunders Company; 2000. p. 443-52.
5. Albanese CT, Rowe MI. Necrotizing enterocolitis. In: O'Neill JA, Rowe MI, Grosfeld JL, Fonkalsrud EW, Coran AG, editors. *Pediatric surgery*, 5th ed, vol. 2. St. Louis: Mosby; 1998. p. 1297-320.
6. Kosloske AM. Necrotizing enterocolitis. In: Oldham KT, Colombani PM, Foglia RP, editors. *Surgery of infants and children: scientific principles and practice*. Philadelphia: Lippincott-Raven Publishers; 1997. p. 1201-14.
7. Peña A. Anorectal malformations: new aspects relevant to adult colorectal surgeons. *Semin Colon Rectal Surg* 1994;5:78-88.
8. Guardino KO. Anorectal malformations in children. In: Wise BV, McKenna C, Garvin G, Harmon BJ, editors. *Nursing care of the general pediatric surgical patient*. Gaithersburg: Aspen Publishers, Inc.; 2000. p. 247-60.
9. Peña A. Anorectal anomalies. In: Spitz L, Coran AG, editors. *Rob & Smith's operative surgery: pediatric surgery*, 5th ed. London: Chapman & Hall Medical; 1995. p. 423-51.
10. Kiely EM, Peña A. Anorectal malformations. In: Spitz L, Coran AG, editors. *Rob & Smith's operative surgery: pediatric surgery*, 5th ed. London: Chapman & Hall Medical; 1995. p. 1425-48.
11. Puri PHirschsprung's disease. In: Oldham KT, Colombani PM, Foglia RP, editors. *Surgery of infants and children: scientific principles and practice*. Philadelphia: Lippincott-Raven Publishers; 1997. p. 1277-300.
12. Holschneider A, Ure BM. Hirschsprung's disease. In: Ashcraft W, editor. *Pediatric surgery*, 3rd ed. Philadelphia: W. B. Saunders Company; 2000. p. 453-72.
13. Teitelbaum DH, Coran AG, Weitzman JJ, Zeigler MM, Kane T. Hirschsprung's disease and related neuromuscular disorders of the intestine. In: O'Neill JA, Rowe MI, Grosfeld JL, Fonkalsrud EW, Coran AG, editors. *Pediatric surgery*, 5th ed., vol. 2. St. Louis: Mosby; 1998. p. 1381-424.
14. Haga LJ. Neonatal intestinal obstruction, part II. In: *Suturline* 1999;7:1-4.
15. Rescorla FJ. Meconium ileus. In: O'Neill JA, Rowe MI, Grosfeld JL, Fonkalsrud EW, Coran AG, editors. *Pediatric surgery*, 5th ed., vol. 2. St. Louis: Mosby; 1998. p. 1159-72.
16. Groff DB. Meconium disease. In: Ashcraft W, editor. *Pediatric surgery*, 3rd ed. Philadelphia: W. B. Saunders Company; 2000. p. 435-42.
17. Newman K. Jejunoileal atresia. In: Oldham KT, Colombani PM, Foglia RP, editors. *Surgery of infants and children: scientific principles and practice*. Philadelphia: Lippincott-Raven Publishers; 1997. p. 1193-200.
18. Millar AJ, Rode H, Cywes S. Intestinal atresia and stenosis. In: Ashcraft W, editor. *Pediatric surgery*, 3rd ed. Philadelphia: W. B. Saunders Company; 2000. p. 406-24.
19. Kalia YN, Nonato LB, Lund CH, Guy RH. Development of skin barrier function in premature infants. *J Invest Dermatol* 1998;111:320-6.
20. Lund C. Prevention and management of infant skin breakdown. *Nurs Clin North Am* 1999;34:907-20.
21. Evans NJ, Rutter N. Development of the epidermis in the newborn. *Biol Neonate* 1986;49:74-80.
22. Hoath SB, Narendran V. Adhesives and emollients in the preterm infant. *Semin Neonatol* 2000;5:289-96.
23. Garvin G. Skin care considerations in the neonate for the ET nurse. *J Enterostomal Therapy* 1990;17:225-30.
24. Darmstadt GL, Dinulos JG. Neonatal skin care. *Pediatr Clin North Am* 2000;47:757-82.
25. Nix DH. Factors to consider when selecting skin cleansing products. *J Wound Ostomy Continence Nurs* 2000;27:260-7.
26. Ittmann PI, Bozynski ME. Toxic epidermal necrolysis in a newborn infant after exposure to adhesive remover. *J Perinatol* 1993;13:476-7.
27. Harpin V, Rutter N. Percutaneous alcohol absorption and skin necrosis in a preterm infant. *Arch Dis Childhood* 1982;57:825.
28. Schick JB, Milstein JM. Burn hazard of isopropyl alcohol in a neonate. *Pediatrics* 1981;68:587-8.
29. Kuller JM, Lund CH. Assessment and management of integumentary dysfunction. In: Kenner C, Brueggemeyer A, Gunderson L, editors. *Comprehensive neonatal nursing: a physiologic perspective*. Philadelphia: WB Saunders; 1993. p. 742-81.
30. Irving V. Reducing the risk of epidermal stripping in the neonatal population: an evaluation of an alcohol free barrier film. *J Neonatal Nurs* 2001;7:5-8.
31. Erwin-Toth P, Doughty DB. Principles and procedures of stomal management. In: Hampton BG, Bryant RA, editors. *Ostomies and continent diversions: nursing management*. St. Louis: Mosby; 1992. p. 29-104.
32. Wilson RE. Ostomy care for infants with necrotizing enterocolitis. *J Wound Ostomy Continence Nurs* 1994;21:190-4.
33. Lund C. Skin care in the intensive care nursery: part III stoma care. *Neonatal Network* 1984; December: 28-34.
34. Garvin G. Caring for children with ostomies and wounds. In: Wise BV, McKenna C, Garvin G, Harmon BJ, editors. *Nursing care of the general pediatric surgical patient*. Gaithersburg: Aspen Publishers, Inc.; 2000. p. 261-78.
35. Boarini JH. Principles of stoma care for infants. *J Enterostomal Therapy* 1989;16:21-5.
36. Hagelegans NA, Janusz HB. Pediatric skin care issues for the home care nurse: Part 2. *Pediatr Nurs* 1994;20:69-76.
37. Motomatsu K, Adachi H, Uno K. Two infant deaths after inhaling baby powder. *Chest* 1979;75:448-50.
38. Pairedeau PW, Wilson GR, Hall MA, Milne M. Inhalation of baby powder: an unappreciated hazard. *BMJ* 1991;302:1200-1.
39. Association of Women's Health, Obstetric and Neonatal Nurses, National Association of Neonatal Nurses. Evidence-based clinical practice guideline: neonatal skin care. AWHONN, 2001.